

American Dental Association
Center for Continuing Education and Lifelong Learning
SEMINAR SERIES

Update
On Esthetic
Restorative Dentistry

By
Dr. Terry Donovan

ADA American
Dental
Association®
Center for Continuing Education
and Lifelong Learning

211 East Chicago Avenue
Chicago, Illinois 60411-2678
P: 312-440-2908 F: 312-440-2915

UPDATE ON ESTHETIC RESTORATIVE DENTISTRY

TERRY DONOVAN D.D.S.

SYNOPSIS

The contemporary restorative dentist has a host of options with which to help his or her patients. Many of these options are considerably less invasive than many of our conventional restorative therapies. Many patients present for esthetic restorative treatment, and are becoming increasingly sophisticated in their expectations of the final results. Additionally, manufacturers are bringing a myriad of new products to the market, often accompanied by a blizzard of information purported to demonstrate the benefits and efficacy of these new products.

This presentation will analyze both successful and failed cases to delineate the procedures essential for success with conventional and contemporary adhesive restorative dentistry. An objective comparative evaluation of many of the newer products on the market will also be given, with an emphasis placed on clinical manipulation of these products.

TOPICS TO BE COVERED INCLUDE:

1. Essentials for soft tissue esthetics in fixed prosthodontics.
2. Effective gingival displacement.
3. New materials and techniques for fabrication of provisional restorations.
4. Adhesive Restorative Dentistry
 - enamel bonding
 - dentin bonding
 - review of conventional and contemporary composite resins
 - diagnosis and restoration of class V lesions
 - materials and techniques for posterior composites
 - prevention of post-operative sensitivity
 - controversies regarding curing lights
 - lab processed composites and poly-glass materials
 - porcelain veneers, inlays and onlays
5. Restoration of the Worn Dentition

COURSE OBJECTIVES

At the end of this course participants should be able to:

1. Understand the critical determinants of soft tissue management with metal-ceramic and all-ceramic crowns, including requirements for tooth preparation and gingival displacement.
2. Understand the differences between different all-ceramic crowns systems, and know which systems to consider and which to avoid.
3. Understand the importance of quality provisional restorations and know which material and technique to use in specific clinical situations.
4. Understand the differences between enamel and dentin bonding, and the differences between different dentin bonding agents.
5. Understand the indications and contra-indications of various posterior restorative materials.
6. Understand the materials and procedures that should be used to eliminate post-operative sensitivity.
7. Understand the complex etiologies related to the worn dentition.
8. Understand preventive strategies to prevent wear and erosion in young patients and how to treat advanced wear cases.

Predictable aesthetics with metal-ceramic and all-ceramic crowns: the critical importance of soft-tissue management

TERRY E. DONOVAN & GEORGE C. CHO

The metal-ceramic crown was introduced to the profession over 4 decades ago. At the time there was tremendous excitement generated by the concept because it theoretically combined the aesthetics of the porcelain jacket crown with the potential for clinical longevity (27). However, it is likely safe to state that most clinicians were somewhat disappointed by the initial clinical results obtained with this treatment modality. It is highly likely that most early aesthetic failures with metal-ceramic restorations were due to a combination of errors in tooth preparation, cervical margin design and soft-tissue management. Nevertheless, the disappointment with metal-ceramic restorations was the genesis for the development of numerous all-ceramic alternatives to the metal-ceramic restoration.

The past 2 decades has witnessed the unprecedented introduction of alternatives to the metal-ceramic crown (1, 2, 4, 10, 14, 33, 34, 37, 47, 48, 53, 55, 60, 61). In addition, many different techniques for fabrication of all-porcelain labial margins have been developed to improve the inherent aesthetic performance of metal-ceramic restorations (Fig. 1, 2) (15, 29, 45, 46, 56, 57). In clinical situations with sufficient remaining enamel, etched porcelain laminate veneers may also be considered to restore the teeth to both optimum aesthetics and function (Fig. 3) (9, 23, 25, 36). Thus, the contemporary clinician has a host of indirect alternatives for the aesthetic restoration of anterior teeth. It is also clear that ceramic technology has matured to the point that it is possible to mimic nature and provide restorations that defy detection to even the trained observer (Fig. 4).

However, it is equally clear that the clinical results achieved by most of the profession fall far short of

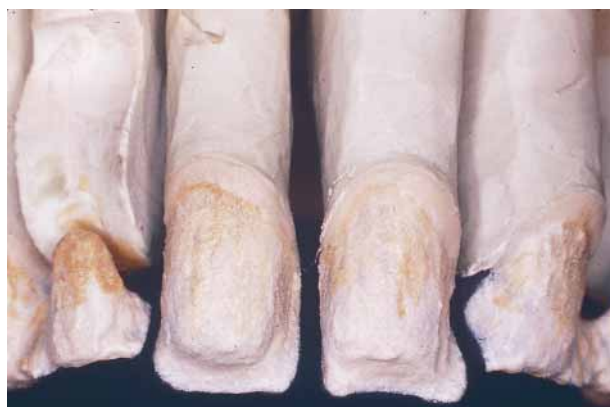

Fig. 1. The routine use of intrinsic coloration and all-porcelain labial margins has significantly improved the aesthetics of metal-ceramic restorations. Note the textured opaque that enhances light refraction.

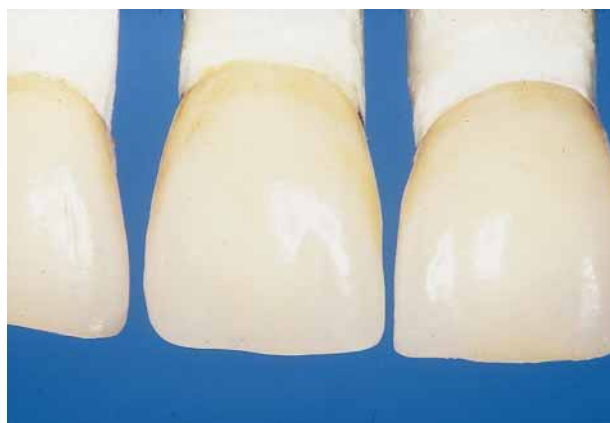

Fig. 2. These anterior crowns with all-porcelain labial margins demonstrate excellent aesthetics in the cervical third of the restorations.

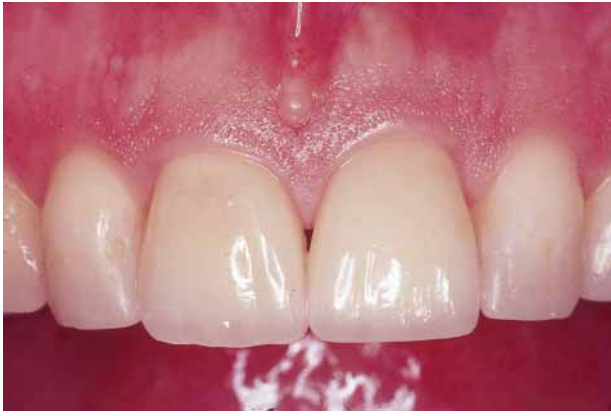

Fig. 3. Because of the contact lens effect, porcelain veneers can be placed with supragingival margins, thereby insuring an optimal periodontal response.

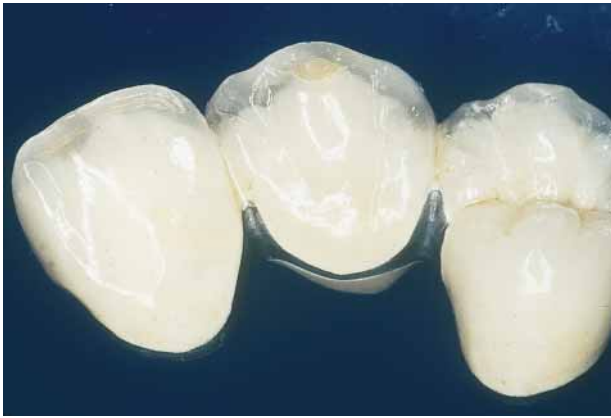

Fig. 4. With intrinsic coloration techniques and translucent body and incisal porcelains, natural aesthetics can be achieved with contemporary metal-ceramic restorations.

this lofty goal. Failure to obtain optimum results probably has less to do with the restorative medium chosen than it does with failure to adequately prepare the soft and hard tissues to receive the restorations (Fig. 5, 6) (8, 16). In order to achieve aesthetic and functional success with any and all of these modalities, it is imperative that the clinician first bring the gingival tissues to optimal health prior to definitive tooth preparation and maintain this state of health through the provisional stage (7, 13, 17). Finally the clinician must understand the nature of the restorative materials to be utilized and prepare the teeth adequately in the correct planes to provide sufficient room for the chosen materials. He or she must also accurately communicate the aesthetic treatment plan to a laboratory technician or cera-

mist capable of fabricating restorations of the highest caliber (35).

It is beyond the scope of this chapter to discuss all the important parameters essential for success with anterior indirect restorations. However, we strongly believe that excellent clinical results can be achieved with many different ceramic systems providing that the soft tissue is managed properly, the teeth are adequately prepared and a quality laboratory technologist is used. The details regarding optimum tooth preparation are well known and have been adequately described elsewhere (43, 50, 51). Cervical margin geometry with ceramic restorations is well understood and has also been thoroughly discussed (19).

This chapter discusses the essentials of soft tissue management inherent in intracrevicular restorative dentistry related to anterior teeth. The clinician faces two basic problems with soft tissue management. In

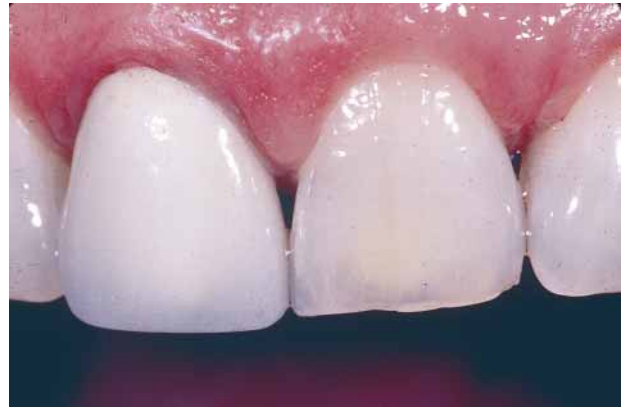

Fig. 5. This metal-ceramic crown is an aesthetic failure due to under-preparation and poor soft tissue management.

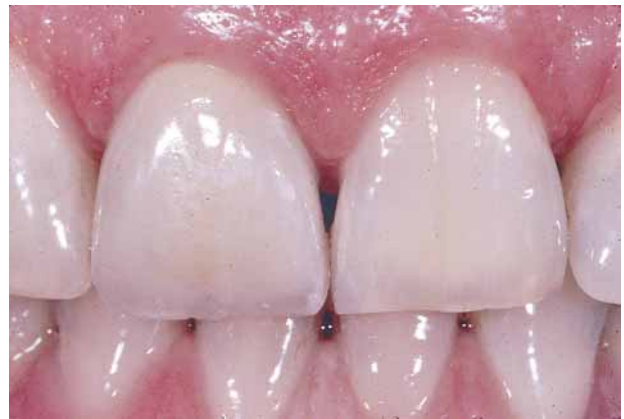

Fig. 6. The crown shown in Fig. 5 was replaced with a Captek restoration after the tooth was adequately prepared.

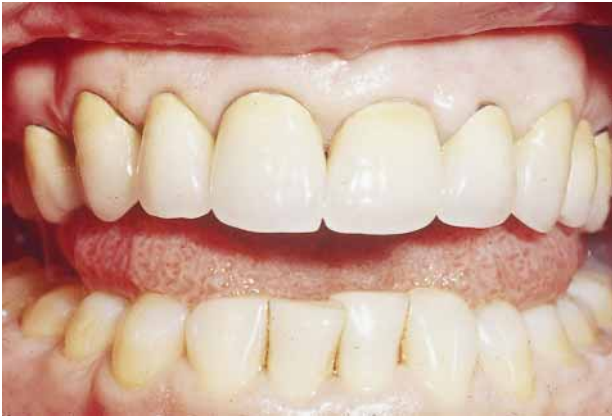

Fig. 7. These anterior teeth have been adequately prepared, but are aesthetic failures due to poor choice of margin geometry and recession due to poor soft tissue management.

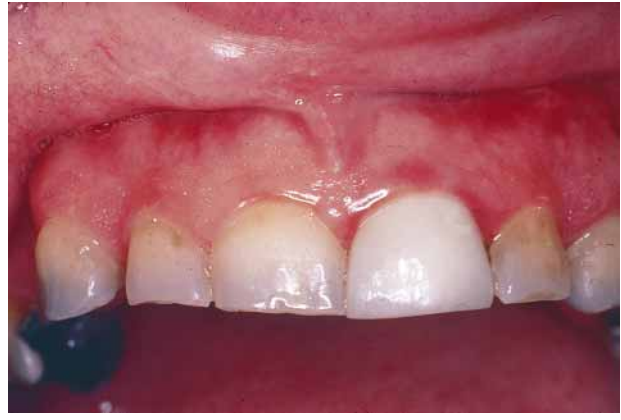

Fig. 9. This restoration has failed due to improper tooth preparation resulting in over-contour and opacity, and poor soft tissue management in the form of biological width violation.

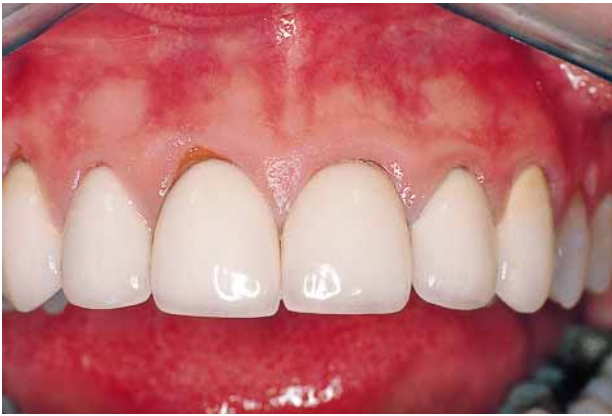

Fig. 8. These anterior restorations have failed due to mediocre laboratory support and recession due to improper soft tissue management.

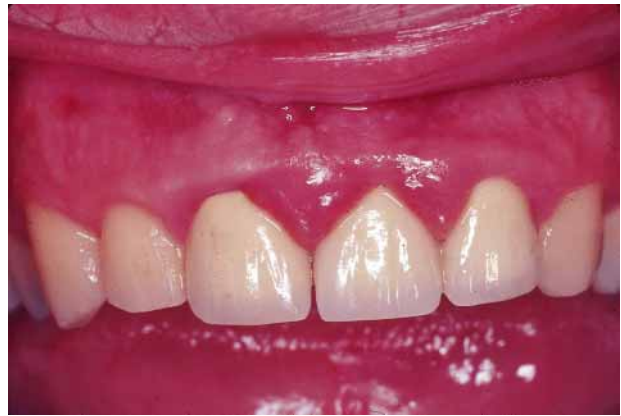

Fig. 10. These restorations are overcontoured due to inadequate tooth preparation, and the chronic inflammatory response is due to biological width violation.

the situations in which restorative margins are to be placed in the gingival sulcus and are intended to be hidden by healthy gingival tissues, the goal is to maintain tissue health and at the same time prevent recession and subsequent exposure of the restorative margin (Fig. 7, 8). The second problem is to place the restoration deep enough in the sulcus to avoid detection and at the same time keep the margin an appropriate distance from the attachment or crest of the alveolar bone so that biological width is not violated (Fig. 9–11) (24, 26, 41).

Preventing gingival recession

It is important to understand that gingival recession is not an inevitable consequence of aging but rather

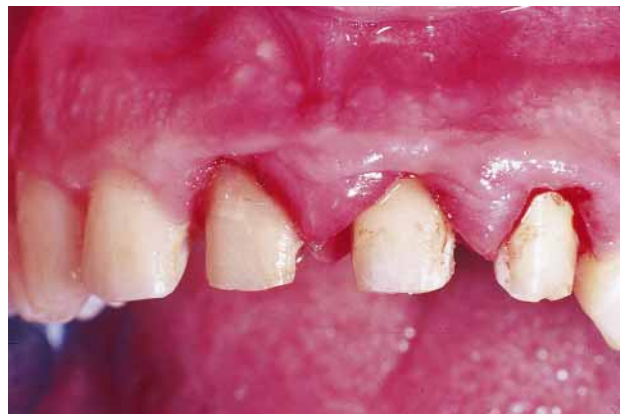

Fig. 11. After removal of the restorations in Fig. 10, the under-reduction of the teeth for metal-ceramic restorations is evident. Note that the cervical finish lines are located deep in the gingival crevice.

a result of some sort of pathogenic process. If excellent gingival health is attained prior to definitive margin placement and appropriate restorative techniques are utilized during therapy, the relationship between the prepared cervical margin and the gingival tissues can be very stable over the long term. This assumes adequate professional maintenance and personal oral hygiene over the long term.

There are five major strategies for preventing gingival recession when placing anterior indirect restorations, and all are primarily under the control of the clinician. These strategies include:

- attaining optimum soft tissue health prior to impression making;
- minimizing iatrogenic soft tissue trauma during margin placement and gingival displacement procedures;
- providing provisional restorations of excellent quality;
- eliminating all excess temporary cement; and
- waiting an appropriate time period to allow the tissues to heal after periodontal surgical therapy.

The first, and perhaps most important strategy, is attaining optimum soft tissue health prior to determining the final cervical margin location and making the final impression. This principle is self-evident but is often ignored in the interests of expediency.

It is highly unlikely that a patient requiring multiple anterior indirect restorations would present with optimum soft tissue health (39). The clinical diagnosis may range from mild gingivitis to chronic periodontitis, and it is critical that an accurate diagnosis be made and that the appropriate therapy be initiated. In situations with significant periodontal destruction, this is usually accomplished.

However, with mild gingivitis, the teeth are often prepared, provisional restorations are fabricated and impressions are made at the same appointment. This expedited approach is a prescription for disaster. First, the gingival inflammation complicates what should be relatively simple, innocuous gingival displacement and impression procedures. More importantly, it is reasonable to assume that the patient will make an improved effort to comply with oral hygiene procedures during the provisional phase or after cementation of the expensive definitive restorations. When this occurs, the gingival inflammation will resolve or at least be reduced, in which case the tissues move in an apical direction, frequently exposing the crown margins. This may occur either

during the provisional phase or after cementation of the definitive restorations. In either situation, the clinician is faced with a catastrophic aesthetic failure.

The ideal approach is to delay final margin location determination until after the gingival tissues have attained a state of optimum health. In most situations with multiple anterior restorations, the teeth are prepared after initial scaling and prophylaxis, with cervical margins in a supragingival position. Excellent indirect provisional restorations are fabricated that restore optimum crown contours, provide excellent marginal integrity, provide access for optimum oral hygiene procedures and provide for occlusal and interproximal stability and patient comfort (20, 32, 44, 62). In addition, these provisional restorations should provide important diagnostic information to the clinician and can be altered intraorally until approved aesthetically by the patient. At this point, the provisional restorations can serve as the blueprint for the definitive restoration, and the clinician can move forward to the laboratory phase of restoration fabrication with confidence (13, 17).

After quality provisional restorations have been provided, definitive periodontal therapy is performed. When adequate healing has occurred and the tissues are deemed healthy using conventional clinical parameters, gingival enhancement is achieved by placing the patient on a weak chlorhexidine rinse (such as Peridex[®], Colgate-Palmolive, Cincinnati, OH) for 2 weeks (54). The optimum location for the cervical margin in the gingival crevice is determined, and the margin dropped to this predetermined position. Specific criteria for this margin placement will be given later in this chapter. At this juncture the provisional restorations are relined or remade to restore marginal integrity, impressions are made and the patient is instructed to continue use of the mouthrinse until the definitive restorations are permanently placed.

In order to avoid iatrogenic recession, it is critical that the rotary instrumentation used to drop the cervical finish line to its final intracrevicular position not damage the soft tissue. A gingival retraction cord soaked in water should be placed into the sulcus for 3–5 minutes prior to margin preparation. After removal of the cord, a defined space will permit precision placement of the finish line with minimal chance for iatrogenic trauma. The use of rotary instruments specifically designed to minimize damage is highly recommended (Abrasive Technology Tissue Protection Diamonds, Premier Dental Products, Norristown, PA) (Fig. 12).




Fig. 12. These tissue protection diamonds are specifically designed to prevent trauma to the soft tissues when dropping cervical finish lines to their final intracrevicular position.

It is also critical that the attachment apparatus not be iatrogenically damaged during gingival displacement procedures. Much of the iatrogenic damage that occurs during gingival displacement is a result of placing a cord deep in the sulcus of inflamed tissues. The previously articulated philosophy of attaining optimal gingival health prior to definitive margin placement, coupled with a finish line that is by design placed a short distance into the gingival sulcus, permits relatively atraumatic retraction procedures. A retraction cord of the appropriate diameter (Ultrapack Retraction Cord, Ultradent Products, Salt Lake City, UT) soaked in a documented hemostatic agent (Hemodent, Premier Dental Products) should be placed into the gingival sulcus for 8–10 minutes (18, 40). One critical procedure to prevent damage at this juncture is to thoroughly soak the retraction cord with water prior to removal from the gingival sulcus. Histological evaluation has demonstrated that removal of a dried cord from the sulcus tears the inner epithelial lining, initiates bleeding and may cause irreversible recession (3).

The attainment of optimal tissue health prior to impression making, the use of gingival enhancement and use of an atraumatic preparation, displacement and impression technique are all critical components of effective soft tissue management and the prevention of recession. An equally important component is the fabrication of provisional restorations of excellent quality. This area of therapy is too often neglected by many practitioners, and the restorations provided can at best be termed “temporaries”. The provisional restorations may be made early in the restorative sequence as part of the healing phase

of therapy or after the preparations are finalized. No matter where in the sequence they are fabricated, the provisional restorations must have appropriate crown contours and excellent marginal integrity and provide adequate aesthetics. It is beyond the scope of this chapter to discuss techniques for provisional fabrication, and that information is readily available (20, 32, 44, 62). We prefer a combination indirect and direct technique, but whatever technique is utilized, the aforementioned criteria must be met.

Cementation of the provisional restorations is a critical step. If all-ceramic restorations are planned, a non-eugenol cement should be used to prevent any inhibition of polymerization of the resin cement with eugenol contained in zinc-oxide eugenol cements (49). If a conventional cement such as glass-ionomer or zinc-phosphate is to be used for the definitive restorations, a zinc-oxide eugenol temporary cement (Temp-Bond, Kerr Dental Mfg., Romulus, MI) is preferred. While zinc-oxide eugenol cements are no longer considered obtundant to pulpal tissues, they do provide an excellent initial seal of the preparation perhaps due to their anti-microbial effects, and this seems to eliminate or reduce sensitivity during the provisional stage. Zinc-oxide eugenol is, however, a potent soft tissue irritant, and regardless of which type of temporary cement is used, it is critical to remove every remnant of temporary cement from the sulcus before dismissing the patient.

This may seem like a rather mundane recommendation, but at the termination of a long appointment it is very easy for the operator to be less than meticulous with excess cement removal, and any speck of temporary cement left in the sulcus will result in gingival inflammation. This inflammatory reaction is reversible upon removal of the irritant, but often a slight amount of recession will occur subsequent to the healing process. This recession, however slight, is detrimental to the long-term goal of hiding the margin beneath healthy tissue.

Patients requiring multiple anterior restorations frequently also require definitive periodontal surgical therapy for pocket elimination or crown lengthening. In these situations it is critical to delay gingival displacement and impression procedures after the surgery to allow sufficient time for stabilization of the gingival crest. Many experts believe that a waiting period of 6 to 8 weeks is sufficient to attain adequate stability, but for many patients this time frame is too short. One excellent study demonstrated that, in many patients, the gingival crest tissues continued to recede for 5 to 6 months after the surgical

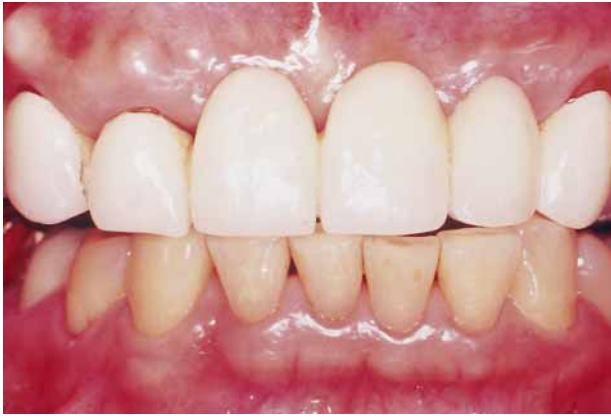

Fig. 13. This fixed partial denture is not acceptable due to recession of the gingival tissues.

procedure (58). It appears empirically that patients with thin, scalloped gingival tissues are more prone to recession than those with thick, flat tissues. This prolonged waiting period of 5 to 6 months would seem to be essential with the former type of patient. These patients will obviously be wearing provisional restorations for a prolonged period, and a recommended precautionary procedure is to remove and re-cement these provisional restorations approximately every 6 weeks to prevent leakage and subsequent recurrent caries.

In summary, recession of the gingival tissues associated with anterior crown placement is preventable. Attainment of optimum gingival health prior to determination of the final margin location is mandatory. Atraumatic tooth preparation and gingival displacement techniques are essential. Fabrication of quality provisional restorations is perhaps one of the most important factors for predictable success. Meticulous removal of excess temporary cement is obviously critical. Finally, provision must be made for tissue shrinkage after periodontal surgical procedures. If all these strategies are utilized and patient compliance is gained with oral hygiene procedures, placement of anterior restorations with minimal gingival recession is predictable and so is the expected outcome (Fig. 13–15).

Gingival inflammation

While gingival recession exposing restorative margins is a frequent occurrence with anterior restorations, a far more pervasive problem is that of chronic marginal inflammation associated with restorations with subgingival margins. Many years ago such in-

flammation was attributed to poor oral hygiene, and patients were admonished to improve their oral hygiene practices, usually to no avail.

With metal-ceramic restorations, the configuration of the cervical margin can affect plaque accumulation due to inherent differences in roughness. Highly polished metal margins or glazed porcelain margins are certainly smoother and less conducive to plaque accumulation than disappearing margins with a critical interface area of oxidized metal and opaque and porous body porcelain (6, 28, 38, 59). The use of disappearing shoulder margins should be discouraged because of this inherent roughness and potential for plaque accumulation and concomitant gingival inflammation.

While both oral hygiene and cervical margin design may be causative factors for gingivitis, the primary causative factor with chronic gingival inflam-

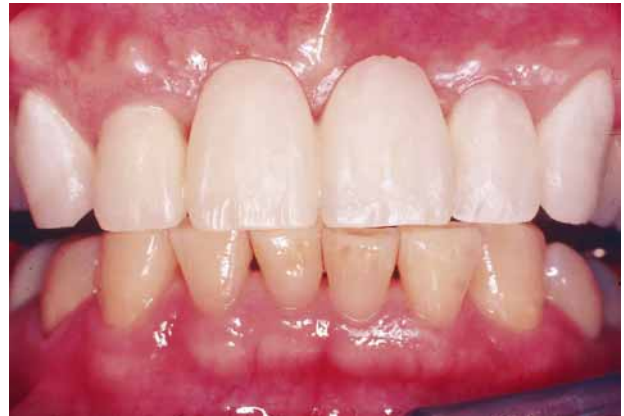

Fig. 14. An acrylic resin provisional restoration has replaced the fixed partial denture in Fig. 13 and will act as the blueprint for the definitive restoration.

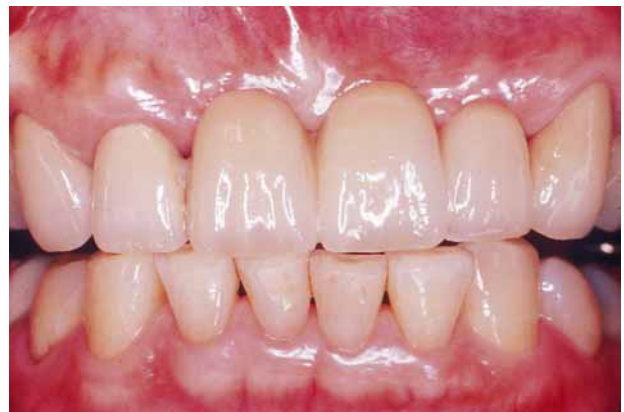

Fig. 15. This metal-ceramic fixed partial denture essentially duplicates the aesthetic result achieved with the provisional restoration in Fig. 14.

mation surrounding anterior restorations is violation of biological width (Fig. 16, 17) (24, 26, 41). For many years, clinicians were taught that the margin of choice with metal-ceramic crowns was a metal collar, and aesthetics were theoretically achieved by attempting to hide the metal margin deep in the gingival sulcus. The folly of this approach has been known for many years, and contemporary clinicians generally utilize all-porcelain margins where indicated, thus eliminating the necessity for placing the margins deep in the gingival sulcus.

However, it is tempting for many clinicians to place cervical finish lines deep into the sulcus with the objective of preventing margin exposure in the event some gingival recession does occur. This is precisely the wrong approach. Placing the margin deep into the sulcus creates difficulties with gingival retraction and increases the likelihood that irreversible damage leading to recession might occur. In addition, clinical studies on margin location indicate that the closer the restorative margins are placed to the epithelial attachment, the poorer is the periodontal response (21, 22, 42). Expressed in reverse, the studies show the further a restorative margin is from the attachment, the better is the soft tissue response.

Specific recommendations have been made in the literature. One popular philosophy is to place the prepared finish lines 0.5 mm from the healthy free gingival margin (5). This concept addresses the inherent variability among operators when attempting to determine the location and depth of the attachment. Because of this demonstrated inability to consistently determine the position of the periodontal attachment, the healthy free gingival margin is used as the best available anatomic landmark. This is a compromise, but for most practitioners is an acceptable solution. A more precise philosophy is to sound through the attachment with a periodontal probe to determine the exact location of the alveolar crest. This concept places cervical margins no closer than 3.0 mm from the measured alveolar crest (30, 31).

Given these recommendations for cervical margin placement, we believe that most finish lines are placed in a position that is too deep into the sulcus. It is likely that the cause of chronic inflammation around the majority of anterior restorations is biological width violation due to the location of the margins relative to the attachment. The major error made by many clinicians is the failure to follow the anatomic sculpting of the tissues and alveolar bone, especially in the interproximal area, and thus interproximal margins are placed too close to the attachment (Fig. 18, 19).

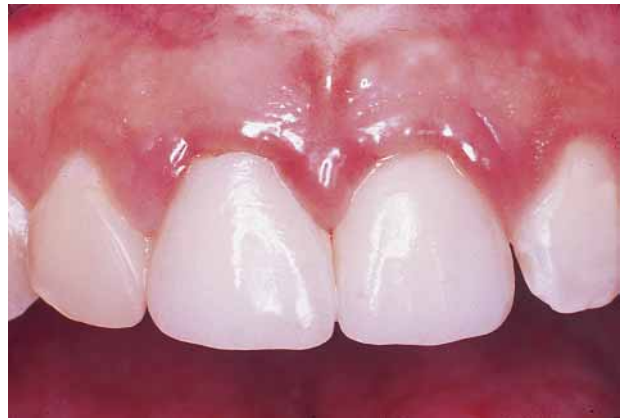

Fig. 16. Soft tissue management is equally as important with all-ceramic crowns as it is with metal-ceramic crowns. Note the biological width violation resulting from margins placed too deep in the gingival sulcus.

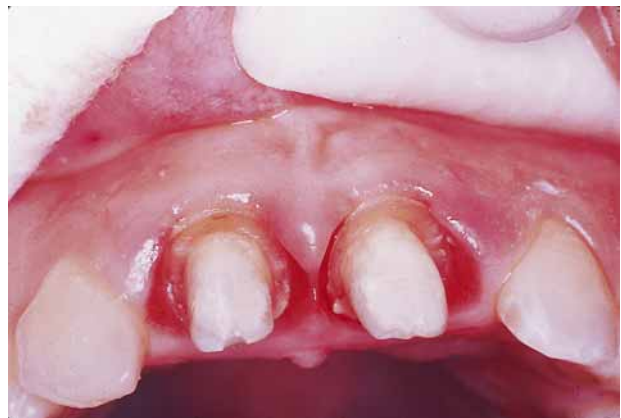

Fig. 17. The all-ceramic crowns in Fig. 16 have been removed. The cervical finish lines are too deep primarily in the inter-proximal areas, where the preparations have failed to follow the scalloped pattern of the soft tissues and underlying alveolar crest.

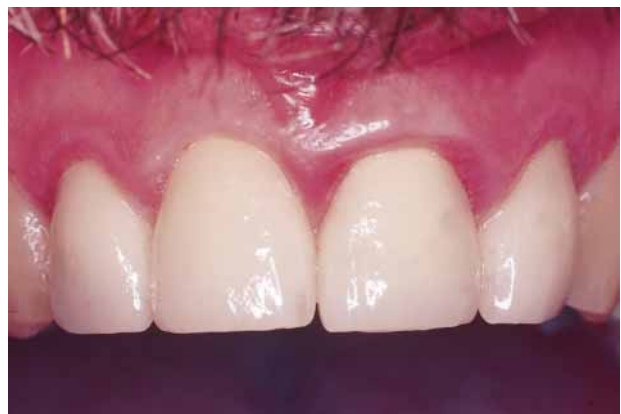

Fig. 18. The chronic inflammatory response around these anterior crowns is a result of margins placed too deeply in the sulcus.

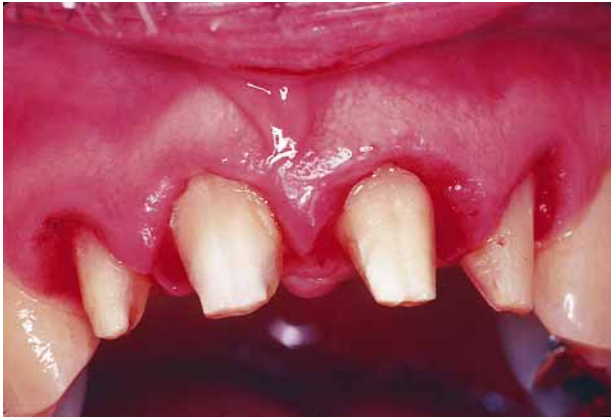

Fig. 19. After the crowns in Fig. 18 have been removed, it is clear the margins had been placed too deep into the sulcus. Crown lengthening will be required to move the attachment to a more apical position.

Most authorities recommend that, whenever possible, cervical margins should be placed in a supragingival location to obtain optimum soft-tissue health (52). Other advantages resulting from supragingival margins are ease of impression making and improved ability to evaluate the quality of the margins (11). With porcelain laminate veneer restorations, such an approach is recommended due to the inherent translucency of the veneers, which creates a “contact lens effect” and effectively blends the veneer imperceptibly into the cervical portion of the tooth (Fig. 3) (36).

However, when crown restorations are required, cervical margins are generally placed in an intracrevicular location, as it is usually impossible to blend in crowns imperceptibly with tooth structure. It is important to consider the patient’s individual smile prior to determining the specific margin location when placing anterior restorations. As many as 25% of patients display no anterior gingival tissues with a normal or even exaggerated smile (12). With the appropriate informed consent, it is possible to place crown margins in a supragingival location in these patients without compromising the functional aesthetic result. This supragingival positioning of the cervical margins greatly simplifies any problems with soft tissue management.

In summary, chronic marginal inflammation associated with anterior restorations can be prevented by placing crowns with smooth, precise margins in the proper intracrevicular position. That position is a relatively short distance into the sulcus (0.5 mm) as measured from the crest of healthy gingival tissues. Margins must be a minimum of 3 mm from the al-

veolar crest, and patients must be instructed in and encouraged to perform optimum oral hygiene procedures (Fig. 20–22). Finally, depending on the initial diagnosis and level of disease, an appropriate recall and maintenance program must be initiated.

Summary and conclusions

The many advances that have occurred in the field of fixed prosthodontics and ceramics allow fabrication of metal-ceramic and all-ceramic restorations that mimic nature and frequently deny detection. However, no matter how natural and lifelike such restorations may be, the final aesthetic result depends most on the health of the surrounding gingival tissues. The key to success is effective soft tissue

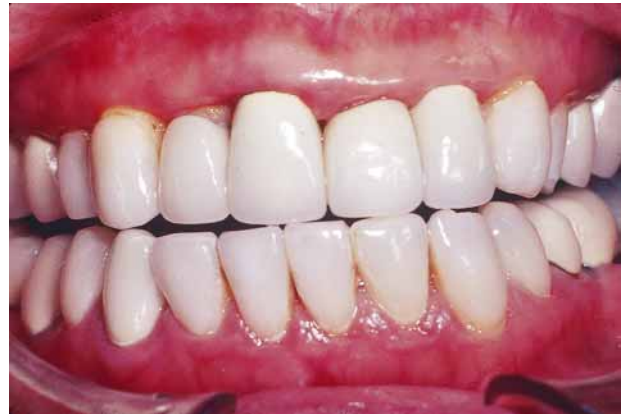

Fig. 20. These anterior restorations have several aesthetic deficiencies both in terms of the restorations themselves and the soft tissue management.

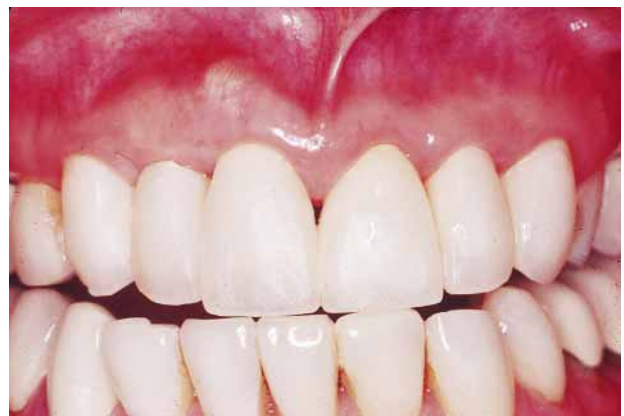

Fig. 21. After the appropriate periodontal therapy for the patient illustrated in Fig. 20, acrylic resin provisionals were fabricated and tested intraorally to develop optimum aesthetics.

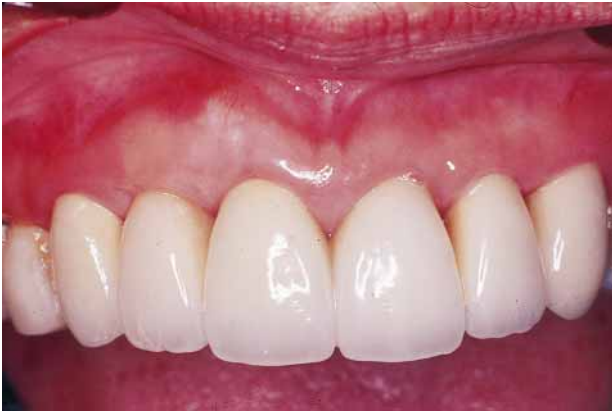

Fig. 22. The definitive restorations basically duplicate the aesthetic result achieved with the provisional restoration in Fig. 21.

management with the primary goal of healthy gingival tissues covering sound, smooth restorative margins.

The essential details of effective soft tissue management have been explained. It is important to understand that these principles are equally important with both metal-ceramic and all-ceramic crowns. Meticulous attention to detail is essential and will result in a high degree of predictable success regardless of which restoration is chosen.

References

1. Adair PJ, Grossman DG. The castable ceramic crown. *Int J Periodontics Restorative Dent* 1984; **4**: 32–46.
2. Andersson M, Oden A. A new all-ceramic crown, a dense-sintered, high-purity alumina coping with porcelain. *Acta Odontol Scand* 1993; **51**: 59–64.
3. Anneroth G, Nordenram A. Reaction of the gingiva to the application of threads in the gingival pocket for taking impressions with elastic materials. *Odontol Revy* 1969; **20**: 301–310.
4. Anusavice KJ. Recent developments in restorative dental ceramics. *J Am Dent Assoc* 1993; **124**: 72–84.
5. Block PL. Restorative margins and periodontal health: a new look at an old problem. *J Prosthet Dent* 1987; **57**: 683–689.
6. Chan C, Weber H. Plaque retention on teeth restored with full-ceramic crowns. *J Prosthet Dent* 1986; **56**: 666–671.
7. Cho GC, Chee WWL. Custom characterization of the provisional restoration. *J Prosthet Dent* 1993; **69**: 529–532.
8. Cho GC, Donovan TE. The versatile and esthetic metal-ceramic crown. *J Calif Dent Assoc* 1996; **24**: 39–43.
9. Cho GC, Donovan TE, Chee WWL. Clinical experiences with bonded porcelain laminate veneers. *J Calif Dent Assoc* 1998; **26**: 121–127.
10. Cho GC, Donovan TE, Chee WWL. Rational use of contemporary all-ceramic crown systems. *J Calif Dent Assoc* 1998; **26**: 113–120.
11. Christensen GJ. Marginal fit of gold inlay castings. *J Prosthet Dent* 1966; **16**: 297–301.
12. Crispin BJ, Watson JF. Margin placement of esthetic veneer crowns. I. Anterior tooth visibility. *J Prosthet Dent* 1981; **45**: 278–280.
13. Derbabian K, Donovan TE, Marzola R, Cho GC, Arcidiano A. The science of communicating the art of esthetic dentistry. II. Diagnostic provisional restorations. *J Esthet Dent* 2000; **12**: 238–247.
14. Donovan TE. Contemporary ceramic restorations: a comparative evaluation. *Alpha Omegan* 1988; **81**: 57–64.
15. Donovan TE, Adishian S, Prince J. The platinum bonded crown: a simplified technique. *J Prosthet Dent* 1984; **51**: 273–275.
16. Donovan TE, Cho GC. Soft tissue management with metal-ceramic and all-ceramic restorations. *J Calif Dent Assoc* 1998; **26**: 107–112.
17. Donovan TE, Cho GC. Diagnostic provisional restorations in restorative dentistry: the blueprint for success. *J Can Dent Assoc* 1999; **65**: 272–275.
18. Donovan TE, Gandara BK, Nemetz H. Review and survey of medicaments used with gingival retraction cords. *J Prosthet Dent* 1985; **53**: 525–531.
19. Donovan TE, Prince J. An analysis of margin configurations with metal-ceramic crowns. *J Prosthet Dent* 1985; **53**: 153–157.
20. Fisher DW, Shillingburg HT, Dewhirst RB. Indirect temporary restorations. *J Am Dent Assoc* 1971; **82**: 160–163.
21. Flores-de-Jacoby L, Zafiroopoulos GG, Ciancio S. The effect of crown margin location and periodontal health. *Int J Periodontics Restorative Dent* 1989; **9**: 197–205.
22. Frelich MA, Niekrash CE, Katz R, Simonsen RJ. Periodontal effects of fixed partial denture retainer margins: configuration and location. *J Prosthet Dent* 1992; **67**: 184–190.
23. Friedman MJ. The enamel-ceramic alternative: porcelain veneers vs. metal-ceramic crowns. *J Calif Dent Assoc* 1992; **20**: 27–33.
24. Gargiulo AW, Wentz FM, Orban B. Dimensions and relations of the dentogingival junction in man. *J Periodontol* 1961; **32**: 261–267.
25. Horn HR. Porcelain laminate veneers bonded to etched enamel. *Dent Clin North Am* 1983; **27**: 671–684.
26. Ingber JS, Rose LF, Coslet JG. The biologic width: a concept in periodontics and restorative dentistry. *Alpha Omegan* 1977; **70**: 62–65.
27. Jones DW. Development of dental ceramics. An historical perspective. *Dent Clin North Am* 1985; **29**: 621–644.
28. Keenan MP, Shillingburg HT. Effects of cast gold surface finishing on plaque retention. *J Prosthet Dent* 1980; **43**: 168–173.
29. Kessler JC, Brooks TD, Keenan MP. The direct lift-off technique for constructing porcelain margins. *Quintessence Dent Technol* 1986; **10**: 145–150.
30. Kois JC. Altering gingival levels: the restorative connection. I. Biologic variables. *J Esthet Dent* 1994; **6**: 3–9.
31. Kois JC. The restorative-periodontal interface: biologic parameters. *Periodontol* 2000 1996; **11**: 29–38.
32. Krug RS. Temporary crowns and bridges. *Dent Clin North Am* 1975; **19**: 313–320.
33. Lehner C, Studer S, Brodbeck U, Scharer P. Short-term results of IPS-Empress full-porcelain crowns. *J Prosthodont* 1997; **6**: 20–30.
34. Malament KA. Considerations in posterior glass-ceramic

- restorations. *Int J Periodontics Restorative Dent* 1988; **8**: 32–49.
35. Marzola R, Derbabian K, Donovan TE, Arcidianocono A. The science of communicating the art of esthetic dentistry. I. Patient-dentist-patient communication. *J Esthet Dent* 2000; **12**: 131–138.
36. Materdomini D, Friedman MJ. The contact lens effect enhancing porcelain veneer esthetics. *J Esthet Dent* 1995; **7**: 99–103.
37. McLean JW. New dental ceramics and esthetics. *J Esthet Dent* 1995; **7**: 141–149.
38. McLean JW, Wilson AD. Butt-joint vs. beveled gold margin in metal-ceramic crowns. *J Biomed Mater Res* 1980; **14**: 239–250.
39. Nemetz H. Tissue management in fixed prosthodontics. *J Prosthet Dent* 1974; **31**: 628–636.
40. Nemetz H, Donovan TE, Landesman HM. Exposing the gingival margin. A systematic approach to the control of hemorrhage. *J Prosthet Dent* 1984; **51**: 647–651.
41. Nevins M, Skurow HM. The intracrevicular restorative margin, the biologic width, and the maintenance of the gingival margin. *Int J Periodontics Restorative Dent* 1984; **4**: 30–49.
42. Newcomb GM. The relationship between the location of sub-gingival crown margins and gingival inflammation. *J Periodontol* 1974; **45**: 151–154.
43. Preston JD. Rational approach to tooth preparation for ceramo-metal restorations. *Dent Clin North Am* 1974; **21**: 683–689.
44. Preston JD. A systematic approach to the control of esthetic form. *J Prosthet Dent* 1976; **35**: 393–402.
45. Prince J, Donovan TE. The esthetic metal-ceramic margin: A comparison of techniques. *J Prosthet Dent* 1983; **50**: 185–192.
46. Prince J, Donovan TE, Presswood RG. The all-porcelain labial margin for metal-ceramic restorations: a new concept. *J Prosthet Dent* 1983; **50**: 793–806.
47. Probst L. Four-year clinical study of glass-infiltrated, sintered alumina crowns. *J Oral Rehabil* 1996; **23**: 147–151.
48. Rinke S, Huls A. Copy-milled aluminous core ceramic crowns: a clinical report. *J Prosthet Dent* 1996; **76**: 343–346.
49. Rosenstiel S, Gegauff A. Effects of provisional luting cements on provisional resins. *J Prosthet Dent* 1988; **59**: 29–33.
50. Scoble HO, Donovan TE. Tooth preparation for indirect esthetic restorations. *J Calif Dent Assoc* 1990; **18**: 31–36.
51. Shillingburg HT, Hobo S, Whitsett LD, Jacobi R, Brackett SG. *Fundamentals of fixed prosthodontics*. 3rd edn. Chicago: Quintessence Books, 1997.
52. Silness J. Periodontal conditions in patients treated with dental bridges. III. The relationship between the location of the crown margins and the periodontal condition. *J Periodontal Res* 1970; **5**: 225–229.
53. Sorensen JA, Choi C, Fanuscu MI, Mito WT. IPS Empress crown system: three-year clinical trial results. *J Calif Dent Assoc* 1998; **26**: 130–136.
54. Sorensen JA, Doherty FA, Newman MG, Flemmig TE. Gingival enhancement in fixed prosthodontics. I. Clinical findings. *J Prosthet Dent* 1991; **63**: 100–107.
55. Sozio RB, Riley EJ. The shrink-free ceramic crown. *J Prosthet Dent* 1983; **49**: 182–187.
56. Toogood GD, Archibald JE. Technique for establishing porcelain margins. *J Prosthet Dent* 1978; **40**: 464–466.
57. Vryonis P. A simplified approach to the complete porcelain margin. *J Prosthet Dent* 1979; **42**: 592–593.
58. Wise MD. Stability of gingival crest after surgery and before anterior crown placement. *J Prosthet Dent* 1985; **53**: 20–23.
59. Wise MD, Dykema RW. The plaque-retaining capacity of four dental materials. *J Prosthet Dent* 1975; **33**: 178–190.
60. Wohlwend A, Scharer P. The Empress technique: a new technique for the fabrication of full ceramic crowns, inlays, and veneers. *Quintessence Int* 1990; **16**: 966–978.
61. Wohlwend A, Strub JR, Scharer P. Metal-ceramic and all-porcelain restorations: current considerations. *Int J Prosthodont* 1989; **2**: 13–26.
62. Youdelis RA, Faucher R. Provisional restorations: an integrated approach to periodontics and restorative dentistry. *Dent Clin North Am* 1980; **24**: 285–303.